

---

---

CHAPTER 24

---

# CORONARY ANGIOPLASTY AND INTERVENTIONAL CARDIOLOGY

MICHAEL W. CLEMAN, M.D.

---

---

## INTRODUCTION

---

---

Patients with severe coronary artery disease have traditionally been treated first with drug therapy and then, if necessary, with coronary artery bypass surgery. In the past decade, so-called interventional cardiology devices—angioplasty, atherectomy, lasers, and stents—have opened new vistas for successful treatment of heart disease symptoms with techniques that are far less invasive than traditional surgery. Rather than constructing a new route for blood flow, as in bypass surgery, these procedures open or widen existing ones. For patients in whom cardiovascular drugs are not effective, they offer a major advantage of being performed under local anesthesia, which greatly hastens recovery and as a result lowers cost.

Atherosclerotic plaque is the culprit that creates candidates for these therapies, by virtue of narrowing the coronary arteries. Within the walls of the arteries, plaque deposits containing cholesterol, connective

tissue, and calcium, as well as arterial muscle cells, intrude into the vessels. The plaque deposits ultimately cause stenosis, a narrowing of the lumen, or inner orifice of the blood vessels, which limits the space available for blood circulation and, consequently, the amount of blood delivered to the heart muscle.

Over time, as this process continues, the reduced delivery of blood means that the heart muscle does not get enough oxygen. This condition, called ischemia, may trigger chest pain, or angina pectoris—a major indicator of coronary artery disease. Approximately 6 million Americans suffer from angina, which can range in severity from mildly annoying to the feeling of a viselike grip in the chest that radiates to the left shoulder, left arm, or jaw. Angina attacks are most often provoked by physical exertion, when the heart needs more oxygen than it does at rest.

Sometimes a diseased coronary artery becomes totally blocked by a blood clot, and a heart attack ensues. If the ischemia has been silent—without pain—the heart attack may be the first indication that there is advanced atherosclerosis. Whatever the se-

quence of events, severely narrowed arteries require treatment, either to lessen the pain or to prevent an initial or a subsequent heart attack. (See Chapter 11.)

---



---

## BALLOON ANGIOPLASTY

---



---

Increasingly, balloon angioplasty (technically called percutaneous transluminal coronary angioplasty, or PTCA) has replaced or has been combined with coronary bypass surgery to open blocked coronary arteries. As its name implies, the procedure actually uses a miniature balloon which, when inflated inside a coronary artery, compresses plaques against the artery walls and cracks them to widen the channel through which blood can flow.

The angioplasty procedure was developed by the late Dr. Andreas Gruentzig, who performed the first human procedure at the University of Zurich, Switzerland, in the fall of 1977. The technique was adopted quickly in the United States, where doctors in New York and California performed the first angioplasties simultaneously in March 1988. From then on it was adopted rapidly, growing from 2,000 procedures performed in 1979 to more than 227,000 in 1988.

The advantage of the angioplasty procedure for physicians is that it is a faster and less invasive method to treat atherosclerotic plaque buildup. Angioplasty patients experience a quicker and less painful recovery. The procedure requires only a two- to three-day hospital stay and recuperation time is minimal. Coronary artery bypass surgery, which involves opening the chest cavity, requires several hours under general anesthesia and necessitates a week or two in the hospital, followed by several weeks more of recuperation for a patient to mend completely at home. (See box, "Advantages and Disadvantages of Angioplasty.")

### IDENTIFYING ANGIOPLASTY CANDIDATES

Although balloon angioplasty sounds like the ideal therapy for patients with angina that does not respond to medication, it is not right for everyone. For example, a patient with triple vessel disease—that is, blockages in three or more coronary arteries—is generally a better candidate for bypass surgery. Angioplasty is more appropriate for a person who has significant blockage of only one or two arteries that causes recurrent angina and restricts his or her daily

## Advantages and Disadvantages of Angioplasty

### Advantages

Can be performed under local anesthesia.

Recovery is shorter and less painful compared to surgery.

Less expensive than surgery.

May be feasible for patients unable to withstand surgery.

There is no noticeable scar.

### Disadvantages

Generally used only for single- or double-vessel disease.

Is less efficient if there are many points of stenosis in a single artery.

May not be effective if plaque is calcified (hardened).

Restenosis rate is 25–35 percent with first procedure; may have to be repeated.

Cannot be used if occlusion is located in area not reachable with catheter.

activities. Angioplasty may be suitable for a person who experiences angina during mild to moderate exercise. It may also be appropriate for a person with silent ischemia who has had a heart attack and is subsequently found to have one or two significantly narrowed vessels. Finally, angioplasty may be suitable for a patient who has had reclosure of a saphenous vein or left internal mammary artery graft used for previous coronary bypass surgery.

The ideal—though by no means the only—candidate for angioplasty has a single, well-defined obstruction in the left anterior descending, left circumflex, or right coronary artery; good heart function (pumping quality) as shown on diagnostic tests; angina that cannot be controlled by drugs and that affects quality of life; and good general health that would not be expected to pose complications for the procedure. Sometimes two dilations may be done in a single vessel if it is narrowed in two places in close proximity.

The presence of coronary heart disease does not automatically qualify a candidate for angioplasty. To begin with, not all plaques respond to the angioplasty technique. Lesions vary in their size, location, and composition; some are too long or much too calcified—hardened by age—for angioplasty. Some lesions are out of reach of a balloon-tipped catheter.

In other instances, the guide wire used to thread the balloon catheter into the vessel may be unable to

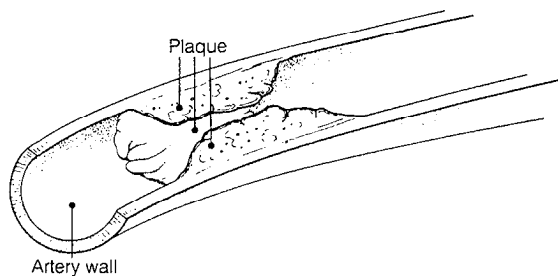
penetrate hardened plaque that has completely clogged (occluded) the artery. Or the patient may have so many stenoses that bypass surgery would restore much more blood flow than would an angioplasty.

### THE PROCEDURE

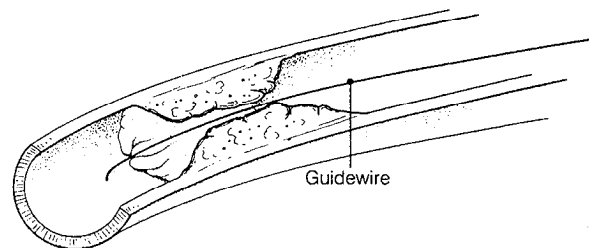
Angioplasty is performed in a cardiac catheterization laboratory. (See Figure 24.1 A-E.) Before the procedure begins the patient is usually given a sedative and will receive local anesthesia at the site of the femoral artery in the groin where the balloon catheter

is introduced. To start the balloon procedure, the operator makes a small incision and inserts a hollow, Teflon-coated guide catheter through the femoral artery and, using a fluoroscope to visualize the path, threads it up toward the heart into the particular coronary artery that contains the blockage. The cardiologist will first confirm the size and location of the obstructions by using the dye to outline the arteries, a procedure known as coronary angiography. (See Chapter 9.)

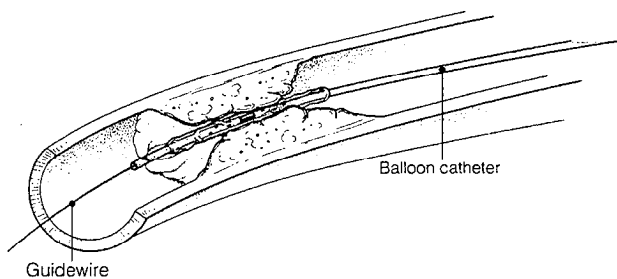
Another catheter, tipped with an inflatable balloon, is then inserted into the guiding catheter and



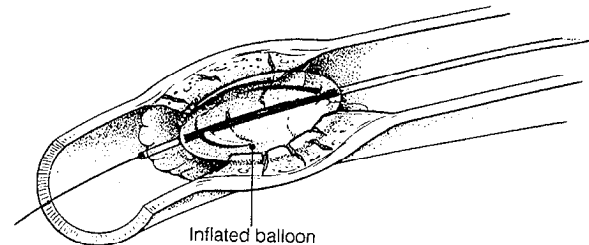
**Figure 24.1A**  
This diagram of an opened artery shows a large buildup of plaque.



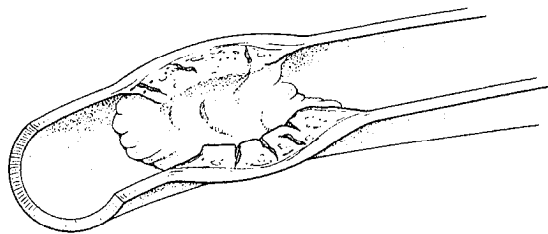
**Figure 24.1B**  
A thin, flexible guidewire is threaded through the coronary artery to go beyond the obstruction.



**Figure 24.1C**  
Next, the catheter containing the deflated balloon is inserted over the guidewire.



**Figure 24.1D**  
The balloon is then inflated (usually several times), compressing the lesion and pushing it back against the arterial wall.



**Figure 24.1E**  
The balloon and catheter are removed, leaving the widened channel.

moved to the point where blood flow is thwarted by a plaque. The plastic balloon itself is tiny and sausage-shaped. Once inflated it will span the width of a normal artery-anywhere from 1/10 to 2/10 inch. A flexible wire (a "bumper" guide wire) extends beyond the deflated balloon tip and is used to navigate the twists and turns of the arterial tunnels of the human body. Once the catheter reaches the site of the blockage, the surgeon looks for an opening in the obstruction through which to pass the balloon. If the plaque has calcified, this may require probing. The deflated balloon is then moved forward over the guide wire, into position next to the lesion in the artery. Dye maybe injected through the balloon so that the operator can gauge the exact location of the lesion, its nature, and its severity on X-ray, and then follow the progress through the procedure.

At the site of each lesion, the physician uses a hydraulic device to suck any air out of the balloon. Then, using a mixture of contrast dye and saline (sterile salt water), it is inflated several times for 30 to 120 or more seconds each time. Each inflation blocks the blood flow and squeezes the lesion back against the arterial wall to restore or enlarge an open channel. The balloon effectively stretches out the blood vessel like an injection mold.

While the plaque isn't removed, the balloon pressure compresses and imbeds it into the wall rather than leaving the lesion loosely attached to the wall.

Upon completion of the procedure, the entire catheter system is pulled out and another angiogram is performed to confirm the results. The small incision is generally closed by direct compression without stitches and the patient is usually sent to the coronary care unit or other special holding area for special observation. After one or two days of observation, the patient will be able to leave the hospital and return to a full range of activities.

A physician will usually follow the patient with periodic exercise stress testing. In selected cases, particularly if there are residual or recurrent symptoms, a repeat angiogram may be recommended in the following months to see how well the procedure holds up. More than 90 percent of angioplasty patients have a good immediate result, defined as an arterial channel that is at least 50 percent open. For the patient, the most obvious indication of this result is the freedom from chest pain.

## COMPLICATIONS

Like all surgical and interventional procedures, angioplasty poses the possibility of complications. A

small percentage of patients experience abrupt closure of the artery during the procedure. This may happen because the artery goes into spasm, is split by the catheter, or is occluded by a blood clot. The physician will reinflate the balloon to open the artery when this happens. But if this fails, or the artery closes after the angioplasty has been completed, emergency bypass surgery may be needed.

About 3 percent of all angioplasty patients experience a heart attack during the procedure—which may then require emergency bypass surgery. Usually this happens when the artery involved in the procedure closes. However, a heart attack maybe triggered by a smaller arterial branch snapping shut because the angioplasty has dislodged a blood clot. If the vessel is small, it is unlikely that emergency surgery will be needed.

The mortality rate for angioplasty in a single vessel is very low, about 0.1 percent (compared to 1 to 2 percent for bypass surgery).

The major problem of angioplasty is the relatively high rate of restenosis, or renewed blockage. Roughly a third of all patients will experience a recurrence of arterial narrowing within the first six months following the procedure. Many kinds of restenosis may occur. Hyperplasia is an overgrowth of cells that is thought to be mediated in part by the body's response to injury—in this case, the cracking of the artery walls during the angioplasty procedure itself. Or the atherosclerotic lesion may grow up again and incorporate a blood clot. But once a patient passes the six-month mark successfully, the likelihood of plaque building up in that particular spot in that artery is much smaller.

The prescription for restenosis generally is another angioplasty. It could take as many as three or four procedures to maintain the patency of the arterial channel.

---



---

## LASER ABLATION

---



---

Angioplasty using a laser instead of a balloon has been developed over the past decade and may prove to be a useful supplement to the treatment of coronary artery disease. Indeed, lasers are increasingly used in conjunction with the balloon technique. It should be noted, however, that laser angioplasty remains an experimental procedure and is available at only a few research centers.

The procedure is similar to that of balloon angio-

plasty, except that the laser catheter is tipped with a metal probe or a fiber optic probe heated by a light beam, which melts through fatty lesions—both stenoses (narrowing) and occlusions (blockages). The laser procedure in some cases surpasses the balloon in its ability to melt away calcified lesions as well.

Generally physicians use a guide wire with a balloon to attack hard plaque first before using a laser. Contrary to popular belief, the laser does not vaporize plaque in a puff of smoke. Rather, the laser ablates, or removes, the lesion layer by layer. The laser homes in and eradicates tiny areas of plaque. The plaque is converted into gaseous products and microscopic particles,

The laser procedure is a delicate one, requiring the surgeon to focus the laser energy on lesions without creating a hole in the wall of artery or making a mechanical puncture. To make laser ablation more effective and safer, researchers still have to perfect the guide wires and the mechanism's overall flexibility for taking the tight corners of the coronary arteries. The equipment will also have to be made more compatible with vascular tissue, so as not to induce spasm or encourage deposition of fibrin (a blood-clotting substance).

A number of different types of lasers are under investigation, but the cool excimer laser appears promising. It delivers energy at an average temperature of 40 degrees Celsius, to avoid cooking or burning the surrounding tissue with short pulses of energy. Others under review include continuous wave laser radiation, such as that emitted by Nd:YAG or CO<sub>2</sub> lasers. These ablate plaque without thermal (heat) damage to the nearby wall.

---



---

## STENTS

---



---

Another way to attack the narrowing of coronary blood vessels is to use a mechanical apparatus called a stent. These tiny metal "scaffolds" are inserted and erected in a collapsing artery to keep it open in a manner similar to the way construction workers might use supports to prop up a collapsing tunnel.

Stents can be used in a variety of medical situations. During angioplasty, they are employed as secondary supports to hold a vessel open while the physician presses back lesions, thus preventing abrupt closure. Stents are also a stopgap measure for patients who aren't immediately medically fit for surgery. That is, the stent may provide temporary pat-

ency (opening) of an artery when a patient who has undergone angioplasty turns out to need an emergency coronary artery bypass graft. Thus, the stent may assist in preventing a heart attack and allow the bypass surgery to be done as an elective rather than an emergency procedure.

The problem of restenosis following angioplasty or laser ablation has galvanized interest in intravascular stents. They can be useful in controlling dissection of the vessel walls after balloon angioplasty or another coronary intervention. Stents provide the means to "tack up" intimal debris (the cells and deposits that accumulate on the intima, the inner surface of the blood vessel walls) and to seal off a tear in the blood vessel wall that may result from angioplasty.

After balloon angioplasty, a stent can be delivered inside a catheter to the site of earlier blockage and expanded within the arterial lumen. The size of a spring in a ballpoint pen, the stent has metal wires that imbed themselves within the intima, the innermost of the three layers of a blood vessel.

A variety of stent designs have been developed. They have received varying degrees of acceptance by the medical community. The Palmaz-Shatz stent is one of the more popular ones. It is a flexible stainless-steel tube that appears meshlike. The device is 1/2 inch long, is as narrow as a piece of spaghetti, and weighs as little as a straight pin.

The potential for developing thrombi (blood clots) is ever present when there has been an injury to the arterial lining. However, successful application of a stent requires a certain amount of clotting, because endothelium cannot grow on bare metal. The cells require a thin layer of fibrin and thrombus (clotting material), and the Shatz stent configuration best allows for the development of fibrin and thrombus together. The stent is completely covered by native blood vessel cells in two to three weeks. The wires themselves become embedded within these cells, which proliferate at the site of implantation.

The use of stents is still in the experimental stage in the United States, and further study is required to determine risks to patients. Very little is known about the long-term effects of putting metal devices in coronary arteries. Patients may need anticoagulation drug therapy for a short time after stent delivery. Researchers must determine whether blood clot formation at the stent site will be a problem and whether stents actually reduce the incidence of restenosis after angioplasty.

Research conducted recently in Europe showed poor results (commonly complete reocclusion or sig-

nificant restenosis) with one particular type of stent, the Wall stent. Newer models, however, especially those impregnated with chemicals that are intended to retard clot formation, may prove more effective. Clearly, more study is needed.

---



---

## ATHERECTOMY

---



---

Another experimental approach to reopening narrow coronary vessels is atherectomy. This procedure uses a rotary device—a high-speed cutting drill mounted on a catheter—that literally shaves off plaque from an artery wall. The main reason for using an atherectomy device is to traverse small and tortuous coronary arteries that are difficult to navigate with thin angioplasty guide wires alone.

A variety of device designs are under review by the medical community. One type, the Auth Rotablator, uses a high-speed oblong burr that may range in diameter from 1.25 to 4.5 millimeters. Imbedded in the bit are fine diamond abrasive particles that whirl at up to 120,000 revolutions per minute to finely ablate the tissue. A flexible driveshaft allows for the passage of a stainless-steel guide wire with a flexible spring tip. The wire moves ahead and can be steered independently from the shaft and the burr, which do not start rotating until the guide wire reaches the plaque in a selected artery.

Once the Rotablator is in place, its operation is similar to that of a dentist's drill. Compressed air or nitrogen powers a turbine to deliver rotational energy to the burr through the driveshaft. The air pressure controls the speed of the burr's rotation. During rotation, sterile saline runs through the catheter sheath to cool the entire system.

The atherectomy device is delivered to the site of the blockage via a catheter, in the same way as the balloon device in conventional angioplasty. Once the device is in place and the drill is turned on, it is allowed to reach a certain rate of rotation before the abrasive tip is advanced over the guide wire. When the physician feels the plaque resist the drill, the tip is successively pulled back and then thrust out again to maintain high-speed rotation. The drill is withdrawn once it punctures the lesion.

Before the rotational device and guide wire are completely withdrawn, dye is injected to verify the quality and success of the procedure. If the stenosis is still sizable, balloon angioplasty may be performed to improve the result.

Grinding plaque in this way has its limits. One concern is that not all the debris (atheroma) will be captured from the far side of the blockage by suctioning the blood around that area, and that this debris may flow through the bloodstream to collect in a smaller artery and cause blockage. Researchers using the Auth Rotablator report that the debris is usually too small to clog capillaries. Other atherectomy devices are designed to capture and hold the atheroma protruding into the vessel in a capsule until it is removed.

The main difference between atherectomy and balloon angioplasty lies in the methods by which they dispatch the plaque in artery walls. Angioplasty splits the plaque and stretches the vessel wall. Atherectomy removes sections of diseased intima and leaves a polished surface devoid of plaques. Compared to laser angioplasty, atherectomy carries a lesser risk of perforation, because the device affords greater control. Also, an atherectomy device can remove calcified lesions while a laser angioplasty usually cannot.

---



---

## VALVULOPLASTY

---



---

Just as atherosclerotic buildup in coronary arteries can be relieved with angioplasty, a heart valve that becomes clogged or narrowed by calcium can be opened by a procedure called valvuloplasty. The valvuloplasty procedure, developed over the last decade, involves opening the valve with a larger balloon-tipped catheter, which is then inflated to press back the calcium in the valve or to correct the anatomical deformity that has caused the narrowing.

All four heart valves are subject to this treatment. Mitral stenosis is a condition in which the mitral valve, which controls blood flow from the left atrium (upper chamber) to the left ventricle (lower chamber) of the heart becomes narrowed, so that blood flow is diminished. In adults, it is most commonly the result of a previous bout of rheumatic fever. Mitral valvuloplasty appears to be relatively successful, producing a restenosis rate of less than 10 percent within the first year.

The aortic valve controls blood flow from the left ventricle to the aorta, the blood vessel that carries blood from the heart to various parts of the body. When the aortic valve is affected by stenosis, or narrowing, surgical valve replacement remains preferable, because the disease is a degenerative one, diagnosed increasingly in older patients. Putting in

an artificial valve provides a more favorable outcome than trying to widen the passage. Indeed, restenosis rates for aortic valvuloplasty hover at 50 percent. In some cases, however, the procedure is used to increase blood flow temporarily in aortic valve patients until they are strong enough to undergo surgery for

a new valve. Tricuspid and pulmonic stenosis are quite common but can be treated safely and effectively with balloon valvuloplasty. The short-term and long-term success rates are similar to that seen with mitral valvuloplasty. (For additional information, see Chapter 25.)